

Anaconda™ AAA Stent Graft System for Challenging AAA Anatomy

How endograft platforms perform in infrarenal neck angulations up to 90°.

BY ROBERT H. GEELKERKEN, MD, PhD; ROLAND J. BEUK, MD, PhD;
AND ROBERT MEERWALDT, MD, PhD

The large randomised clinical trials¹⁻⁵ comparing endovascular aneurysm repair (EVAR) with traditional open surgical repair (OSR) in elective infrarenal abdominal aortic aneurysm (AAA) treatment point out that in the first years after treatment, EVAR gives rise to better outcomes. After this initial finding, stent graft migration, ephemeral sealing between the vessel wall and the stent graft, stent breakage, stent component disconnection, prosthetic tearing, and limb occlusion were the causes of increased EVAR failure. Learning from the experience with the first-generation endografts and due to technological advances, there has clearly been improvement in the next generation of commercially available stent grafts. It is fairly reasonable to assume that the present generation of stent grafts allows a more durable outcome in the same circumstances, compared to the first generation used in the randomised clinical trials of the 1990s.

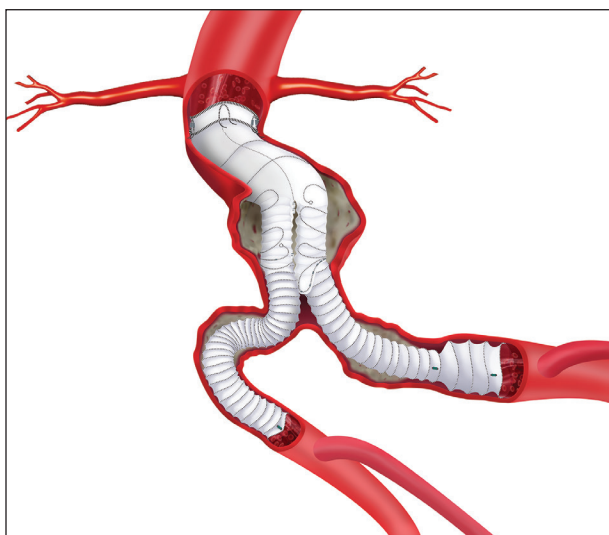


Figure 1. The Anaconda™ AAA Stent Graft System with ONE-LOK™ platform is composed of a three-piece modular track design.

THE ROAD TO THE ANACONDA™ ONE-LOK™ DESIGN

The Anaconda™ AAA Stent Graft System (Vascutek Ltd.) has been designed with the intention of addressing the failure modes observed in the 1990s designs. The first experiences with the Anaconda™ AAA Stent Graft System were encouraging; migration and type I or III endoleak were rarely observed.^{6,7} In 2009, the Anaconda™ AAA Stent Graft System's design was upgraded to the ONE-LOK™ platform, which addressed, among other things, the relatively increased chance of early leg occlusion observed when smaller bodies were combined with larger legs. This version of the Anaconda™ ONE-LOK™ had a three-piece modular track design. The body with two short legs was characterised by two independent proximal sealing rings composed of multiple turns of fine nitinol, active fixation on the second ring due to four independent pairs of nitinol hooks, and zero body column strength in combination with additional body supporting ring stents (Figure 1). During placement, the proximal rings of the body were reconstrainable, allowing multiple rotational and upstream or downstream repositioning. The contralateral gate was preloaded with a magnet-bearing wire, which made contralateral limb cannulation quite simple. The legs were constructed of six to 10 individual turns of nitinol wires in a vacuum cleaner hose of tapered, straight, or flared design creating flexibility and kink resistance. The design of this system creates a convenient platform for challenging cases such as ruptured AAAs (rAAAs) with severely angulated infrarenal necks.

A CASE ON THE FRONTIER OF RAAA TREATMENT

In 2010, an 84 year old man who appeared to be very healthy visited our outpatient department, presenting with a 50 mm asymptomatic AAA. After shared decision making and discussing the option of elective AAA repair, a watchful waiting approach was chosen. The

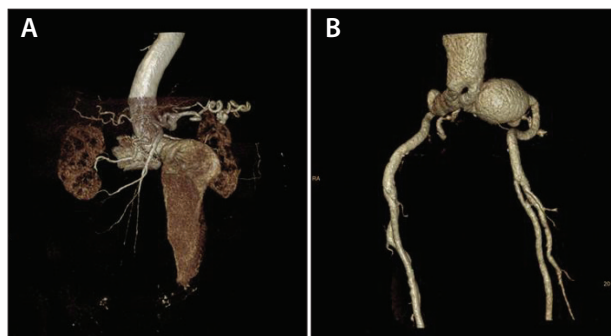


Figure 2. A 3D reconstruction of the proximal AAA anatomy (A) and distal AAA anatomy (B). Due to low flow, two separate CTAs were necessary.

patient did not attend regular visits, including recommended abdominal ultrasound examinations. In 2016, the patient was still living independently. His family doctor admitted him to our emergency department with increasing pain in his back and a painful pulsating abdominal mass.

At admission, the patient was conscious, but his blood pressure dropped to 90/60 mm Hg. He noted that if he was eligible, he preferred EVAR over OSR. An emergency CTA revealed a contained rupture of a 104 to 107 mm rAAA with an infrarenal neck diameter of 20 mm, neck length of 14 mm, and angulation of 75°. Furthermore, both common iliac arteries (CIAs) were very elongated, and the left CIA measured 51 mm in diameter (Figure 2).

Using CT fusion imaging (Discovery IGS 740, GE Healthcare) in our hybrid operating room, we performed ruptured EVAR (rEVAR). The main body delivery system was raised up to the level of the renal arteries, and the body of the Anaconda™ AAA Stent Graft System was released close to the origin of the lowest right renal artery (Figure 3). Thereafter, with three leg components on the left side and two leg components on the right side, the rAAA and the left CIA aneurysm were sufficiently excluded (Figure 4). The patient was admitted to the intensive care unit. He recovered well and was discharged on post-operative day 11 to a rehabilitation centre to prepare for his return home.

TIPS AND TRICKS FOR USING THE ANACONDA™ AAA STENT GRAFT SYSTEM IN CHALLENGING ANATOMY

Our first recommendation is to perform EVAR procedures in a hybrid operating room equipped with a CT fusion imaging system. This technique assists in better understanding of the images, simplifies the procedure, and, consequently, significantly reduces radiation and contrast exposure.⁸ When using this system in AAAs with challenging anatomy, one must be aware of some additional tips and tricks that may be helpful in introducing and placing the stent graft. In cases with severe infrarenal neck angulation, it can be beneficial to aim for a relatively higher oversizing of the body in relation to the infrarenal neck diameter because the release of the body exactly perpendicular to the central lumen line is not achieved in all cases.

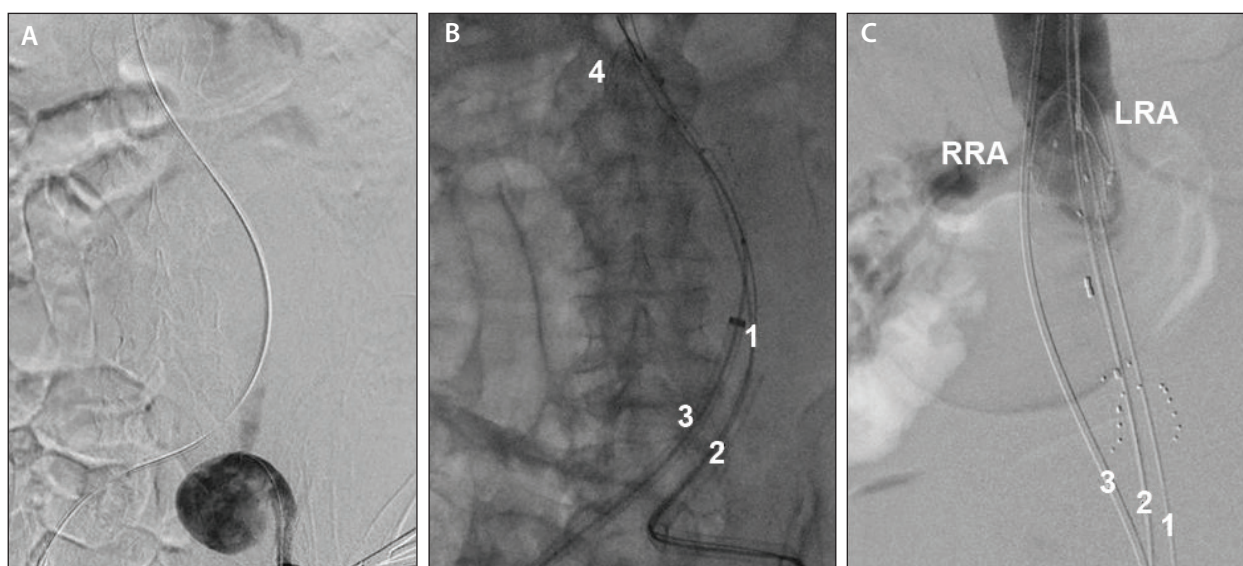


Figure 3. Panel A shows challenging left iliac access. Panel B shows two stiff wires on the left side (1), Check-Flo large introducer sheath (Cook Medical) (2), delivery device (3), and body of the Anaconda™ AAA Stent Graft System (4). Panel C shows a second stiff wire on the left side (1), a stiff wire on the right side of the body delivery system (2), and a straight flush catheter (3).

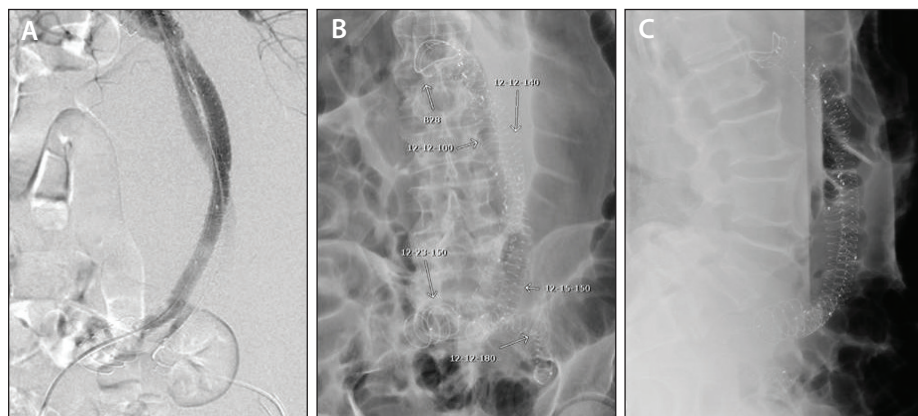


Figure 4. Completion angiogram (A), anteroposterior view of the six components (B), and lateral view (C).

Implantation starts with the routine technique of achieving access in both common femoral arteries by surgical cutdown or by a percutaneous Seldinger approach. Anticoagulation therapy is administered in accordance with the local standard for endovascular procedures. On both sides, one or two stiff wires are introduced up to the aortic arch. To stretch the iliac and aorta angulations further, starting on the contralateral iliac side or on both iliac sides, an 18 or 24 F (inner diameter), 20 to 25 cm long introducer sheath is placed up to the level of the AAA. Next, place the body juxtarenal in a rotated position with no legs in an inner or outer position in relation to the infrarenal angulation (in most cases, one of the legs is situated behind the other in an anteroposterior view). This prevents the outer leg from compressing the inner leg at the level of the neck angulation.

Next, access to the contralateral gate with the magnet wire system is achieved. In up to 95% of cases, contralateral gating is achieved within a few minutes.⁹ The contralateral guiding catheter is pushed forward, up to the level of the visceral arteries, and the magnet wire is interchanged for one or both stiff wires. If there is still a sharp angulation, the contralateral 18 F introducer sheath is pushed forward, up to the level of the infrarenal neck. Through the contralateral guiding catheter or a regular angiography catheter, digital subtraction angiography is performed to visualise the renal artery orifices. The body of the Anaconda™ AAA Stent Graft System could be repositioned upstream or downstream, if indicated.

The marker ring at the top of the contralateral guiding catheter is then placed at the level of the flow splitter 8 marker on the Anaconda™ body, and the length of the contralateral leg is defined using the pull-back technique to the expected level of the CIA bifurcation. The contra-

lateral guiding catheter is removed, and the delivery device with the appropriate contralateral leg is introduced up to the level of the renal arteries. The release wires of the body are pulled out, and the delivery device of the body is removed. The delivery device with the chosen leg on the ipsilateral side is introduced. The large introducer sheaths are simultaneously withdrawn up to the level of both

CIA origins, and both legs are released (similar to the kissing stent technique) with the proximal markers of both legs just below the second body sealing and fixation ring. At the level of the CIAs, the introducer sheaths are withdrawn ahead of the releasing legs. The body and both legs are gently ballooned, and final angiography is performed to assess the patency of the renal arteries, endograft, internal iliac arteries, as well as any early or late endoleaks.

OUTCOMES OF VARIOUS STENT GRAFT SYSTEMS IN CHALLENGING ANATOMY

Anatomical characteristics of AAAs are the most critical factors in achieving successful EVAR outcomes. Challenging anatomy is characterised by > 60° infrarenal angulation or > 90° iliac axis tortuosity, short (< 15 mm) infrarenal neck, or reversed conical and bell-shaped necks. Of these, severe proximal aortic neck angulation has the greatest potential for fixation failure, a situation that may lead to complications including type I endoleak and late rupture. Bench test studies identified that the relative stiffness of a stent graft was responsible for its inability to conform to neck angulation, therefore creating leaks through gaps between the stent graft and the neck. Several publications have discussed the application of endografts in challenging anatomies.

Anaconda™ AAA Stent Graft System

Freyrie et al¹⁰ published a series of 44 AAA patients treated with the Anaconda™ AAA Stent Graft System. All patients had severe angulation of the proximal aortic neck (> 60° angulation) and/or of the iliac arteries (> 90° angulation). Primary technical success was achieved in 100% of patients. At 24 months, survival, primary clinical success, and assisted clinical success rates were 94.2%, 88.2%, and 91.3%, respectively. Two year iliac limb paten-

cy in severely angulated iliac axes was 96.7%. Only one proximal type I endoleak was noted.

In a prospective multi-centre cohort study, Rödel et al¹¹ evaluated the midterm outcomes of using the Anaconda™ system for treating infrarenal AAAs with angulated necks. In a 5 year period, a total of 36 AAA patients with a mean infrarenal neck angulation of 82° were included. Primary technical success was achieved in 30 of 36 patients (83%). Four year primary clinical success was 69%. There was no aneurysm-related mortality. Four patients required conversion to open AAA exclusion. In six of the 36 patients, one or more reinterventions were indicated; five were due to occlusion of one leg or the complete body. The investigators concluded that using the Anaconda™ system to treat AAAs with severely angulated infrarenal necks is feasible, but comes with side effects.

The Anaconda™ ONE-LOK™ platform is also feasible for the management of short-neck infrarenal and juxtarenal aortic aneurysms with fenestrated EVAR (FEVAR). The first Dutch experience including 23 patients who were treated for juxtarenal aneurysms and two patients with short-neck AAAs were reported by Dijkstra et al.¹² A total of 56 fenestrations were incorporated, and 94.6% were successfully cannulated and stented. On completion angiography, three type I endoleaks and seven type II endoleaks were observed. At 1 month follow-up, all endoleaks had spontaneously resolved. There were no aneurysm ruptures or aneurysm-related deaths and no reinterventions. Primary patency at 1 month of cannulated and stented target vessels was 96%.

Aorfix Stent Graft

Sbarzaglia et al¹³ reviewed the available data in the literature regarding the Aorfix stent graft (Lombard Medical, Inc.). They concluded that the high performance of the Aorfix stent graft did not present any significant difference between necks > 60° and < 60°, and in a personal series of 27 patients, they reported a primary technical success rate of 96.3% and an assisted primary technical success rate of 100%.

Powerlink Stent Graft

Experience using the Powerlink stent graft (Endologix, Inc.) has been reported by Qu et al.¹⁴ In a single-centre study, 519 patients underwent EVAR using the Powerlink endograft. There were 54 cases in the short neck group, with lengths of 11 to 15 mm, and 26 cases involving very short necks, with lengths ≤ 10 mm. Angulated necks (37 patients) were defined as ≥ 60° between the longitudinal axis of the infrarenal aorta and the aneurysm. The technical success rate in these 177 challenging anatomy cases was 97.4%. Intra-

operative complications included three conversions due to delivery access problems and six proximal type I endoleaks. The 30 day mortality rate was 1.7%. During follow-up, four proximal type I endoleaks were revised with a proximal cuff and/or Palmaz stent (Cordis Corporation). Limb occlusion occurred in two cases, and the total reintervention rate was 5.3%. There were no stent graft distal migrations, and no post-EVAR ruptures. The investigators concluded that the Powerlink stent graft platform proved safe and effective in treating AAAs with short and angulated necks.

Zenith Endovascular Graft

Forbes et al¹⁵ reported their 5 year, single-centre outcomes in relation to neck length after elective placement of a Zenith endovascular graft (Cook Medical) in 318 patients. They concluded that patients with shorter infrarenal necks (4–15 mm in length) can be treated as effectively as those with longer necks using the Zenith endovascular graft, unless the necks are angulated or dilated.

Endurant Stent Graft System

The Endurant stent graft system (Medtronic) is also part of the next-generation systems designed to expand the applicability of EVAR in challenging anatomy. Verhagen et al¹⁶ and Baston Goncalves et al¹⁷ presented the preliminary results on the Endurant stent graft platform. Technical success was achieved in 90.3% of the patients. No device-related serious adverse events and no device-related deaths were seen during the early follow-up period. Their results support the adequacy of the Endurant stent graft system in the face of adverse neck anatomy. Neck length was the most relevant anatomical limitation for EVAR.

OUTCOMES IN CHALLENGING CASES

In a series of 439 patients treated with EVAR, the observed occlusion rate was 8.8% for those treated with Endurant, 5.8% for Zenith, 2.7% for the Anaconda™ system, and 2.2% for the Excluder endoprosthesis (Gore & Associates), with no statistical differences between these rates.¹⁸ Significant angulation and excessive calcification were independent predictors of leg occlusion.

In the last 50 years, OSR for rAAA has a mortality rate of up to 50% despite rapid hospital transportation, early diagnosis, resuscitation, and improvements in anaesthesia and intensive care treatment.^{19–21} Evidence was raised in several cohort studies that treating patients with rAAAs, including rEVAR whenever possible, achieved good results.^{22–25} Three randomised clinical trials including rAAAs were published^{26–28}; however, the mutual agreement between these trials was that

rEVAR does not improve survival. Remarkably, there was a prominent variance in 30 day mortality in these three trials between 18% to 53% in the rEVAR cohort and between 24% and 53% in the OSR cohort. It seems quite self-evident that study design, patient selection, and 24/7 presence of an experienced EVAR team are the drivers of this huge difference in 30 day mortality between the randomised clinical trials.

A recent systematic review concluded from the available data that there is no difference in the outcomes between rEVAR and OSR, but extrapolation to daily practice is limited by the paucity of data.²⁹ In the last decade, several vascular centres reported their results of treating patients with rEVAR whenever possible. Our experience with rEVAR is reflected in the publication by Rödel et al.³⁰ During a 4 year enrolment period, all 117 consecutive patients presenting with infrarenal rAAAs were assessed for preferential rEVAR treatment. Patients with challenging anatomy (infrarenal neck length < 15 mm and neck angulation > 60°) were included as part of a “damage control” concept. Thirty-five patients (33% of all admitted rAAA patients) were treated with rEVAR; 42% of them were considered haemodynamically unstable (systolic blood pressure < 100 mm Hg), and 30% had challenging AAA anatomy. The 30 day mortality in the rEVAR group was 17%. After a median follow-up of 3.4 years, mortality in the rEVAR cohort was 34%. All deaths were non AAA related. Our study shows that rEVAR is feasible in challenging AAA anatomy regardless of haemodynamic condition and that it is associated with relatively low mortality rates.

Nevertheless, six to seven out of 10 patients remain unsuitable for rEVAR because of inappropriate anatomy. Our preferential rEVAR treatment is also supported by other institutions. Ten Bosch et al³¹ concluded that in EVAR-suitable rAAA patients, an absolute peri-operative mortality reduction of 25.5% with rEVAR versus OSR was achieved, which was still present at 6 months follow-up. In 2013, the nationwide Dutch Surgical Aneurysm Audit was started.³² At the end of 2015, a total of 9,357 patients were included, with 15% rAAAs among them. Roughly 35% of the rAAAs were treated with rEVAR, and the 30 day mortality rate was approximately 26%.

CONCLUSION

The case presented and the literature discussed in this article underline the suitability of the Anaconda™ ONE-LOK™ platform in challenging anatomies. But using FEVAR in these cases challenged the EVAR team in more than one way. Dedicated endovascular skills were needed to compensate geometrical difficulties

during stent placement. The operative procedures were customised to the patient in nearly every individual case. The features of the Anaconda™ AAA Stent Graft System including the repositionability of the two proximal ring stents during deployment, the unsupported and therefore more flexible main body, the three-piece modular platform, and the magnet system all expand the applicability of EVAR in challenging circumstances. ■

Acknowledgments: The authors are grateful to Dr. Edith Willigendaal for her valuable advice in drafting this manuscript.

1. Prinssen M, Verhoeven EL, Buth J, et al. A randomized trial comparing conventional and endovascular repair of abdominal aortic aneurysms. Dutch Randomized Endovascular Aneurysm Management (DREAM) trial group. *N Engl J Med*. 2004;351:1607-1618.
2. Greenhalgh RM, Brown LC, Kwong GP, et al; EVAR trial participants. Comparison of endovascular aneurysm repair with open repair in patients with abdominal aortic aneurysm (EVAR trial 1), 30-day operative mortality results: randomised controlled trial. *Lancet*. 2004;364:843-848.
3. Lederle FA, Freischlag JA, Kyriakides TC, et al. Outcomes following endovascular vs open repair of abdominal aortic aneurysm: a randomized trial. Open Versus Endovascular Repair (OVER) Veterans Affairs Cooperative Study Group. *JAMA*. 2009;302:1535-1542.
4. Greenhalgh RM, Brown LC, Powell JT, et al; United Kingdom EVAR Trial Investigators. Endovascular versus open repair of abdominal aortic aneurysm. *N Engl J Med*. 2010;362:1863-1871.
5. De Bruin JL, Baas AF, Buth J, et al; DREAM Study Group. Long-term outcome of open or endovascular repair of abdominal aortic aneurysm. *N Engl J Med*. 2010;362:1881-1889.
6. Rödel SG, Geelkerken RH, Prescott RJ, et al; ANA 004 study group. The Anaconda AAA stent graft system: 2-year clinical and technical results of a multicentre clinical evaluation. *Eur J Vasc Endovasc Surg*. 2009;38:732-740.
7. Freyrie A, Gallitto E, Gargiulo M, et al. Results of the endovascular abdominal aortic aneurysm repair using the Anaconda aortic endograft. *J Vasc Surg*. 2014;60:1132-1139.
8. Hertault A, Maurel B, Sobocinski J, et al. Impact of hybrid rooms with image fusion on radiation exposure during endovascular aortic repair. *Eur J Vasc Endovasc Surg*. 2014;48:382-390.
9. Freyrie A, Gargiulo M, Rossi C, et al. Preliminary results of Anaconda aortic endografts: a single center study. *Eur J Vasc Endovasc Surg*. 2007;34:693-698.
10. Freyrie A, Testi G, Faggioli GL, et al. Ring-stents supported infrarenal aortic endograft fits well in abdominal aortic aneurysms with tortuous anatomy. *J Cardiovasc Surg*. 2010;51:467-474.
11. Rödel SG, Zeebregts CJ, Huisman AB, Geelkerken RH. Results of the Anaconda endovascular graft in abdominal aortic aneurysm with a severe angulated infrarenal neck. *J Vasc Surg*. 2014;59:1495-1501.
12. Dijkstra ML, Tielu IF, Meerwaldt R, et al. Dutch experience with the Fenestrated Anaconda endograft for short-neck infrarenal and juxtarenal abdominal aortic aneurysm repair. *J Vasc Surg*. 2014;60:301-307.
13. Sbarzaglia P, Grattoni C, Oshoala K, et al. Aorfix device for abdominal aortic aneurysm with challenging anatomy. *J Cardiovasc Surg*. 2014;55:61-70.
14. Qu L, Raithel D. Experience with the Endologix Powerlink endograft in endovascular repair of abdominal aortic aneurysms with short and angulated necks. *Perspect Vasc Surg Endovasc Ther*. 2008;20:158-166.
15. Forbes TL, Harris JR, Lawlor DK, Derosé G. Midterm results of the Zenith endograft in relation to neck length. *Ann Vasc Surg*. 2010;24:859-862.
16. Verhagen HJ, Torsello G, De Vries JP, et al. Endurant stent-graft system: preliminary report on an innovative treatment for challenging abdominal aortic aneurysm. *J Cardiovasc Surg (Torino)*. 2009;50:153-158.
17. Bastos Gonçalves F, Hoeks SE, Teijink JA, et al. Risk factors for proximal neck complications after endovascular aneurysm repair using the Endurant stentgraft. *Eur J Vasc Endovasc Surg*. 2015;49:156-162.
18. Mantas GK, Antonopoulos CN, Sfyroeras GS, et al. Factors predisposing to endograft limb occlusion after endovascular aortic repair. *Eur J Vasc Endovasc Surg*. 2015;49:39-44.
19. Bown MJ, Sutton AJ, Bell PR, Sayers RD. A meta-analysis of 50 years of ruptured abdominal aortic aneurysm repair. *Br J Surg*. 2002;89:714-730.
20. Sadat U, Boyle JR, Walsh SR, et al. Endovascular vs open repair of acute abdominal aortic aneurysms—a systematic review and meta-analysis. *J Vasc Surg*. 2008;48:227-236.
21. Hoornweg LL, Storm-Versloot MN, Ubbink DT, et al. Meta analysis on mortality of ruptured abdominal aortic aneurysms. *Eur J Vasc Endovasc Surg*. 2008;35:558-570.
22. Oranen BI, Bos WT, Verhoeven EL, et al. Is emergency endovascular aneurysm repair associated with higher secondary intervention risk at mid-term follow-up? *J Vasc Surg*. 2006;44:1156-1161.

23. Kapma MR, Groen H, Oranen BJ, et al. Emergency abdominal aortic aneurysm repair with a preferential endovascular strategy: mortality and cost-effectiveness analysis. *J Endovasc Ther.* 2007;14:777-784.
24. Peppelenbosch N, Geelkerken RH, Soong C, et al. Endograft treatment of ruptured abdominal aortic aneurysms using the Talent aortouniiliac system: an international multicenter study. *J Vasc Surg.* 2006;43:1111-1123.
25. Veith FJ, Lachat M, Mayer D, et al. Collected world and single center experience with endovascular treatment of ruptured abdominal aortic aneurysms. *Ann Surg.* 2009;250:818-824.
26. Reimerink JJ, Hoornweg LL, Vahl AC, et al. Endovascular repair versus open repair of ruptured abdominal aortic aneurysms: a multicenter randomized controlled trial. *Ann Surg.* 2013;258:248-256.
27. Powell JT, Sweeting MJ, Thompson MM, et al; IMPROVE Trial Investigators. Endovascular or open repair strategy for ruptured abdominal aortic aneurysm: 30 day outcomes from IMPROVE randomised trial. *BMJ.* 2014;348:f7661.
28. Desgranges P, Koberter H, Katsahian S, et al; on behalf of ECAR investigators. ECAR (Endovasculaire ou Chirurgie dans les Anévrismes aorto-iliaques Rompus): a French randomized controlled trial of endovascular versus open surgical repair of ruptured aorto-iliac aneurysms. *Eur J Vasc Endovasc Surg.* 2015;50:303-310.
29. Badger SA, Harkin DW, Blair PH, et al. Endovascular repair or open repair for ruptured abdominal aortic aneurysm: a Cochrane systematic review. *BMJ Open.* 2016;6:e008391.
30. Rödel SG, Meerwaldt R, Beuk RJ, et al. Endovascular treatment of ruptured abdominal aortic aneurysm: is there a long-term benefit at follow-up? *J Cardiovasc Surg.* 2012;53:83-89.
31. Ten Bosch JA, Teijink JA, Willigendael EM, Prins MH. Endovascular aneurysm repair is superior to open surgery for ruptured abdominal aortic aneurysms in EVAR-suitable patients. *J Vasc Surg.* 2010;52:13-18.
32. Dutch Institute for Clinical Auditing. Jaarrapportage 2015. <https://www.dica.nl/media/332/DICA-jaarrapportage-2015.pdf>. Accessed August 23, 2016.

Robert H. Geelkerken, MD, PhD

Department of Surgery
Division of Vascular Surgery
Medical Spectrum Twente
Faculty of Science and Technology
Experimental Centre of Technical Medicine
University Twente
Enschede, The Netherlands
+31-53-4873442; r.geelkerken@mst.nl

Disclosures: None.

Roland J. Beuk, MD, PhD

Division of Vascular Surgery
Medical Spectrum Twente
Experimental Centre of Technical Medicine
University Twente
Enschede, The Netherlands

Disclosures: None.

Robbert Meerwaldt, MD, PhD

Department of Surgery
Division of Vascular Surgery
Medical Spectrum Twente
Enschede, The Netherlands

Disclosures: None.

The FEVAR team of Medisch Spectrum Twente is supported by unrestricted grants from Vascutek Ltd.